LONDON SPORTS & RHEUMATOLOGY IMAGING

LSRI CPD LIBRARY · FREE TEACHING SLIDES

MRI Essentials: Imaging the Shoulder

Bright or dark, the three planes, a five-step reading order, the rotator cuff and labrum, tear patterns, when to request MRI and the red flags that cannot wait.

Dr Prashant Sankaye
Consultant Musculoskeletal, Sports and Spine Radiologist
MBBS, MS, FCPS, MRCS, FRCR, PGCE (Med), FHEA, PGDip (Sports and Exercise Medicine)

First presented by Dr Sankaye at the Vista Health CPD Programme webinar, 4 November 2026. LSRI edition: the clinic's housekeeping and protocol slides and the live case images are not included.

For physiotherapists, chiropractors, podiatrists, osteopaths, sports therapists, GPs and other clinicians

WHAT WILL WE COVER TONIGHT?

1

How an MRI image is made

Why some tissues are bright and others dark – in plain English

2

Finding your way round

Planes, the rotator cuff and the labrum

3

Multiple live cases

Frozen shoulder, cuff tear, labral tear with paralabral cyst, a tumour, AVN, mixes cases

4

Referring well

When to request MRI, what to write on the form and which red flags cannot wait

BRIGHT OR DARK? A CHEAT SHEET

Tissue	T1	Fluid-sensitive (fat-suppressed T2 / PD)
Fat (subcutaneous, marrow)	BRIGHT	dark (suppressed)
Fluid (effusion, bursitis, cyst, oedema)	dark	BRIGHT
Muscle	mid grey	mid-dark grey
Tendon, ligament, cortical bone	dark	dark

RULE OF THUMB
T1 shows anatomy. Fluid-sensitive images show pathology: a bright signal where it should be dark (in a tendon, labrum or bone) is the thing to look for.

SAME SLICE, TWO SEQUENCES



Fat is bright, fluid is dark. Good for anatomy and marrow.



Fat is dark, fluid is bright. Good for oedema, bursitis, tears and cysts.

On which type of image do fluid and oedema look bright and fat look dark?

THREE PLANES, THREE VIEWS

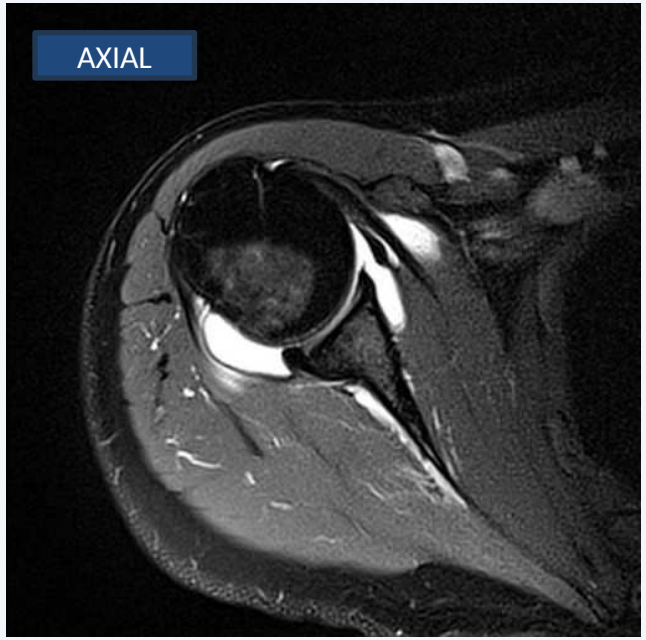

Looking up from the feet

Best for: Labrum, subscapularis, biceps groove



Looking from the front along the supraspinatus

Best for: Supraspinatus, AC joint, subacromial space

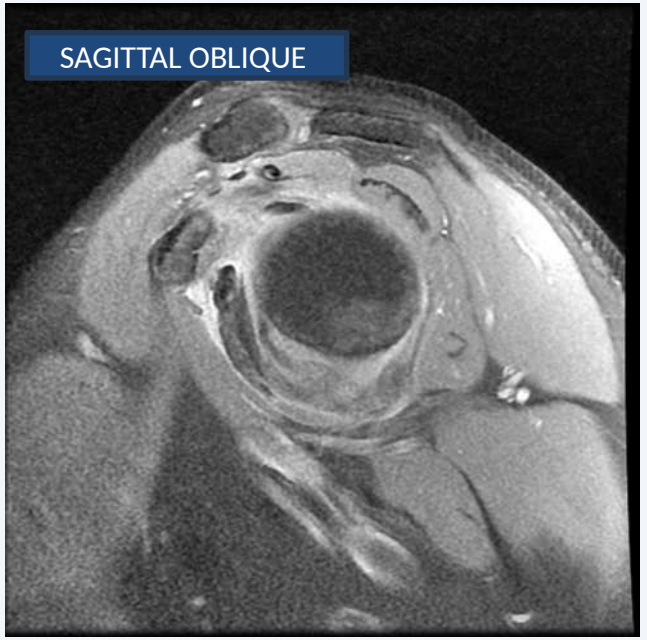

Looking side-on, down the glenoid

Best for: Cuff muscle bulk, rotator interval, acromion shape

A SIMPLE READING ORDER

1

Bone and marrow

Fracture, oedema, AVN, tumour

2

Fluid

Joint effusion, bursitis, cysts, rice bodies

3

Cuff Tendons

Tendinosis, partial or full tear

4

Labrum, capsule, biceps

Tears, instability, thickened capsule

5

Muscle

Bulk, atrophy, denervation oedema

Same five steps every time, so nothing gets missed while you chase the obvious finding.

CORONAL ANATOMY: WHAT ARE YOU LOOKING AT?

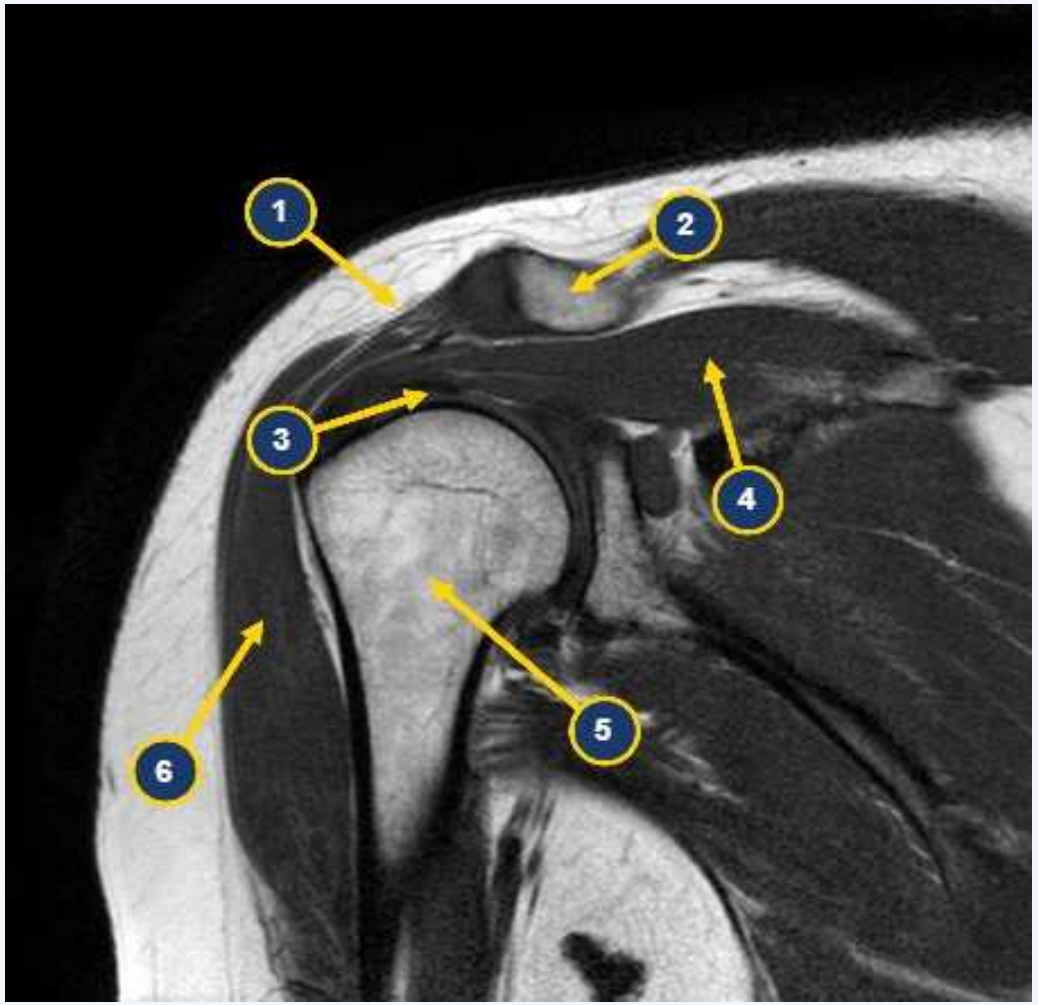

1 Acromion

2 AC joint / distal clavicle

3 Supraspinatus tendon

4 Supraspinatus muscle

5 Humeral head

6 Deltoid

T1 coronal oblique. Fat (marrow, subcutaneous) is bright; tendon and cortex are dark.

THE ROTATOR CUFF: S I T S

S

Supraspinatus

Starts the movement of lifting the arm (abduction)

Most commonly torn. Seen best on coronal and sagittal

I

Infraspinatus

Rotates the arm outwards (external rotation)

Back of the shoulder. Axial and sagittal

T

Teres minor

Rotates the arm outwards, with infraspinatus

Small, lower back tendon. Easy to overlook

S

Subscapularis

Rotates the arm inwards (internal rotation)

Front of the shoulder. Best seen on axial

Which rotator cuff tendon is torn most often?

THE LABRUM: A CLOCK FACE ON THE GLENOID

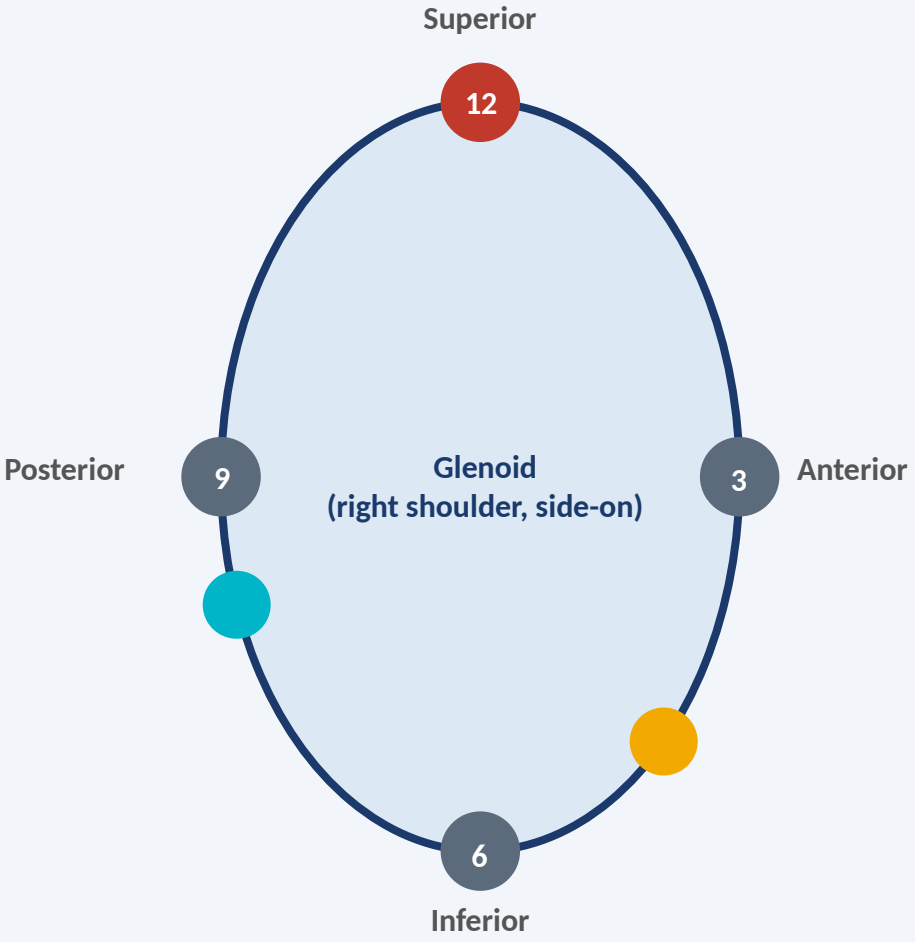

12 O'clock

Top of the labrum, where the biceps tendon anchors. SLAP tear

3-6 O'clock

Front and lower edge. Bankart lesion after an anterior dislocation

7-10 O'clock

Back edge. Posterior labral tear, often with a paralabral cyst/s

HOW A TENDON TEAR LOOKS

Tendinosis



Tendon is thicker and a little brighter, but no fluid-bright gap.

Often degenerative

Partial-thickness tear



Fluid-bright cleft on one surface. The tendon is still in continuity.

Articular, bursal or intratendinous

Full-thickness tear



Fluid-bright gap all the way through. The ends may retract.

Size, retraction and muscle quality matter

Grey = tendon. Cyan = fluid-bright signal on the fluid-sensitive image. Schematic only.

IMAGING AND SYMPTOMS DO NOT ALWAYS MATCH

37% of professional handball players had shoulder symptoms

93% had an abnormal shoulder MRI

So....

Treat the patient, not the picture. MRI findings only matter when they fit the history and examination.

WHEN IS MRI THE NEXT STEP?

Consider MRI when:

- Symptoms persist despite a good trial of conservative care (follow your local pathway)
- Suspected full-thickness cuff tear after injury, especially with weakness
- Suspected labral tear or instability: recurrent dislocation, apprehension, clicking or catching
- An injection or surgery is being considered, and the result will change management

Think When:

- Typical frozen shoulder or straightforward impingement: the diagnosis is clinical
- An X-ray has not been done. Start with a radiograph (arthritis, calcific tendinitis, fracture, AC joint)
- The result will not change what you do

RED FLAGS: DO NOT WAIT 6 WEEKS

- Constant pain that does not ease with rest, especially at night
- Unexplained weight loss, fever or night sweats
- Past history of cancer (breast, lung, prostate, kidney, thyroid, myeloma)
- A lump, bone swelling or marked bony tenderness
- Progressive weakness, wasting or neurological signs
- Hot, swollen joint (possible infection)

NICE NG12 (suspected cancer)

Adults: an X-ray suggesting bone sarcoma needs urgent referral (within 2 weeks).

Children and young people: unexplained bone pain or swelling needs a very urgent X-ray (within 48 hours).

SUMMARY AND KEY TAKE AWAY POINTS

- T1 shows anatomy. Fluid-sensitive images show pathology.
- Read the MRI in the same order every time.
- Frozen shoulder: thick capsule. Cyst next to the glenoid: check the labrum and the nerve.
- Not everything is the cuff: AVN, rice bodies and benign mimics such as elastofibroma exist.
- Treat the patient, not the picture: clinical correlation is yours to do.
- Red flags cannot wait for a course of physio to fail.

LONDON SPORTS & RHEUMATOLOGY IMAGING

Teaching and MDT sessions for your team

Dr Sankaye runs dedicated teaching sessions and MSK imaging MDT meetings for physiotherapy, chiropractic, podiatry, osteopathy and sports therapy teams, and for GP practices. Bring your own cases and scans.

Call +44 20 3633 5040 · info@lsri.uk

More free slides: lsri.uk/cpd-accredited-training/teaching-slides/

LSRI Harley Street, W1G 9QJ · LSRI Northwest London, Harrow HA2 7SJ

LSRI Ltd is a CPD Approved Provider (#790052, The CPD Group). These slides are free educational material for healthcare professionals and are not a substitute for clinical judgement or local guidelines. Any patient images have been anonymised, and slides that could not be anonymised have been removed. You may share this PDF unchanged for non-commercial teaching.