LONDON SPORTS IMAGING

CPD TALK FOR PHYSIOTHERAPISTS

Stress fractures

Seeing what the X-ray misses: MRI grading, high-risk sites and return to sport.



Dr Prashant Sankaye

Consultant Musculoskeletal, Sports and Spine Radiologist

MBBS, MS, FCPS, MRCS, FRCR, PGCE (Med), FHEA, PGDip (Sports and Exercise Medicine)

www.LSRI.uk

STRESS FRACTURES FOR PHYSIOTHERAPISTS

Your speaker

Dr Prashant Sankaye

Consultant Musculoskeletal, Sports and Spine Radiologist

QUALIFICATIONS

MBBS, MS, FCPS, MRCS, FRCR, PGCE (Med), FHEA, PGDip (Sports and Exercise Medicine)

PRACTISES AT

Vista Health/InHealth, Apollo Radiology, London Sports and Rheumatology Imaging

LSRI Harley Street

LSRI Northwest London, Harrow



LSRI

LONDON SPORTS IMAGING

www.LSRI.uk

MRI, ultrasound and guided injections, reported by consultant radiologists.

TODAY

Four parts, four group moments

1

Basics

- Bone stress continuum
- Imaging choices
- Reading MRI signal

Group: warm-up poll

2

Fredericson

- Grades 1 to 4b
- Grade-it ladder
- What a grade means

Group: grade your own MRIs

3

Sites

- Tibia and fibula
- Femoral neck
- Foot and knee

Group: high or low risk?

4

Cases and quiz

- Three short cases
- Six-question quiz
- Take-home points

Group: pairs and teams

Stop me any time. Bring your own cases, and your own MRIs.

WARM-UP SHOW OF HANDS

A runner has three weeks of shin pain. The X-ray is normal.

Can you rule out a stress fracture?

Yes	No	Not sure

PART 1 · BASICS

Bone stress is a continuum

Remodelling

Microdamage is repaired as fast as it appears.

MRI: normal

Stress reaction

Repair falls behind. Oedema, no cortical break.

MRI: grades 1 to 2

Stress fracture

Cortex breached. Signal foci or a fracture line.

MRI: grades 3 to 4b

Complete fracture

Cortex gives way. Displacement is possible.

MRI: gap, displacement

Fatigue fracture

Abnormal load on normal bone. Runners, recruits, dancers.

Insufficiency fracture

Normal load on abnormal bone. Osteoporosis, low bone density.

PART 1 · BASICS

Why did this bone fail?

Training load

Sudden jumps in volume, intensity or surface.

Energy availability

Low intake for output (RED-S). Menstrual disturbance.

Bone health

Low bone density. Low vitamin D or calcium.

History

A previous stress fracture raises the risk of another.

Mechanics and kit

Gait, foot posture, worn shoes. The evidence is weaker.

Your job: find the driver, not just the lesion.

PART 1 · BASICS

Which test answers which question?

Test	Good at	Watch out for
X-ray	First look. Excludes other causes.	Insensitive early: about 10% at first.
MRI	Most sensitive, about 88%. Shows oedema and grade.	Oedema is not always symptoms.
CT	The cortical line, best for anterior tibia.	Misses early marrow change. Radiation.
Bone scan	Very sensitive, whole skeleton.	Not specific. Radiation. Rarely first choice.

Sensitivity figures are approximate and vary by site and study.

PART 1 · MRI BASICS

Reading the signal

STIR OR FAT-SUPPRESSED T2

Fluid and oedema are bright. Look here first.

T1

Marrow fat is bright. Marrow oedema replaces it, so the marrow turns dark.

FRACTURE LINE

Low signal on every sequence, running through the oedema.



Example images shown in the live session



Example images shown in the live session

PART 2

Fredericson grading

Five grades, from a bright rim on the periosteum to a fracture line through the cortex.

PART 2 · FREDERICSON

Grading tibial stress injuries on MRI



Grade 1

Periosteal oedema only



Grade 2

Plus mild marrow oedema on STIR or T2, normal on T1



Grade 3

Plus marrow oedema that is also abnormal on T1



Grade 4a

Plus intracortical signal in multiple foci



Grade 4b

Plus a linear fracture line

Schematic axial tibia. Amber is high signal on STIR. Every grade has periosteal oedema; muscle oedema does not count.

PART 2 · FREDERICSON

Periosteal oedema is not soft-tissue oedema



Periosteal oedema

A thin bright line hugging the cortex. This is the grade 1 finding.



Soft-tissue oedema

Bright signal in muscle or fascia beside the bone. It does not count towards the grade.

> It can sit alongside a bone stress injury, but muscle or fascial oedema alone is not Fredericson grade 1.

FREDERICSON · GRADE 1

Periosteal oedema only



Schematic · axial tibia

ON MRI

A thin bright rim hugging the cortex on STIR. Marrow and cortex are normal. Muscle or fascial oedema does not count.

CLINICALLY

Often the early end of MTSS. Pain after activity, tenderness along the border.

TIME OUT

About 16 days in one series (Kijowski).

Example images shown in the live session

FREDERICSON · GRADE 2

Mild marrow oedema appears



Schematic · axial tibia

ON MRI

Periosteal plus mild marrow oedema. Bright on STIR and T2, still normal on T1.

CLINICALLY

Expect focal tenderness. The hop test may provoke pain.

TIME OUT

Longer than grade 1. Kijowski: about 16 days at grade 1, about 71 days at 4b.

Example images shown in the live session

FREDERICSON · GRADE 3

Marrow oedema reaches T1



Schematic · axial tibia

ON MRI

Extensive marrow oedema: bright on STIR and T2, now dark on T1. The cortex is still intact.

CLINICALLY

Focal tenderness and pain on hopping are expected.

TIME OUT

The same T1 finding is Arendt grade 3: about 12 to 16 weeks estimated.

Example images shown in the live session

FREDERICSON · GRADE 4A

The cortex joins in



Schematic · axial tibia

ON MRI

Marrow oedema plus several small foci of signal inside the cortex. No line yet.

CLINICALLY

A cortical stress fracture in progress. Treat it as a true stress fracture.

TIME OUT

Plan between grade 3 and grade 4b. There is no separate estimate for 4a here.

Example images shown in the live session

FREDERICSON · GRADE 4B

A fracture line you can see



Schematic · axial tibia

ON MRI

A linear low-signal fracture line crossing the cortex, surrounded by marrow oedema.

CLINICALLY

A true stress fracture. Check the site: high-risk sites need an orthopaedic view.

TIME OUT

About 71 days in one series (Kijowski), against about 16 days for grade 1. Arendt grade 4 estimates 16 weeks or more.

Example images shown in the live session

PART 2 · FREDERICSON

Grade it in three questions

Start with true periosteal oedema on STIR, not muscle or fascial oedema. Then ask:

1. Marrow oedema on STIR or T2?

No → **Grade 1**

↓ Yes

2. Marrow also abnormal on T1?

No → **Grade 2**

↓ Yes

3. Any signal change in the cortex? →

- **No: Grade 3**
- **Foci: Grade 4a**
- **Line: Grade 4b**

PART 2 · FREDERICSON

Arendt grading: bone stress injuries, not MTSS

Grade	Marrow signal	Cortex	Estimated rest
Arendt 1	STIR only	Intact	About 3 weeks
Arendt 2	STIR and T2	Intact	3 to 6 weeks
Arendt 3	STIR, T2 and T1	No definite break	12 to 16 weeks
Arendt 4	STIR, T2 and T1	Visible fracture line	16 weeks or more

Why not MTSS

Every Arendt grade needs marrow signal. Periosteal oedema does not change the grade, so Fredericson grade 1 has no Arendt equivalent.

Built for

Athletes with bone stress injuries at many sites, not just the tibia. It added STIR to the Fredericson approach.

Sources: Radiopaedia, MRI grading system for bone stress injuries; Arendt 2003. Rest times are estimates.

PART 2 · FREDERICSON

What the grade means for time out

Arendt grades (marrow-based, non-MTSS). Estimated rest, bars run to the upper estimate.



FREDERICSON 1

16 days

Mean time to return, Kijowski series.

FREDERICSON 4B

71 days

Mean time to return, same series.

Sources: Arendt 2003; Kijowski 2012. Estimates for planning, not prescriptions.

A CAUTION ABOUT THE SCAN

43%

of asymptomatic runners had MRI stress reactions

Match the image to the history and the examination. Treat the athlete, not the scan.

Small series of distance runners (Bergman 2004). A caution, not a prevalence.

PART 3

Where it happens

High-risk and low-risk sites, and how long each takes to heal.

PART 3 · SITES GROUP MOMENT

Know the high-risk sites

High risk

Tension or poor blood supply. Risk of delayed union, displacement, non-union.

- Femoral neck, tension side
- Anterior tibial cortex
- Navicular
- Base of the fifth metatarsal
- Medial malleolus
- Patella
- Talus
- Great toe sesamoids

Lower risk

Usually settle with load management and a graded return.

- Posteromedial tibia
- Fibula
- Metatarsals 2 to 4
- Pubic ramus
- Calcaneus
- Femoral neck, compression side

Source: Boden and Osbahr 2000. Lower risk does not mean no risk.

PART 3 · SITES

Time back to sport depends on the site

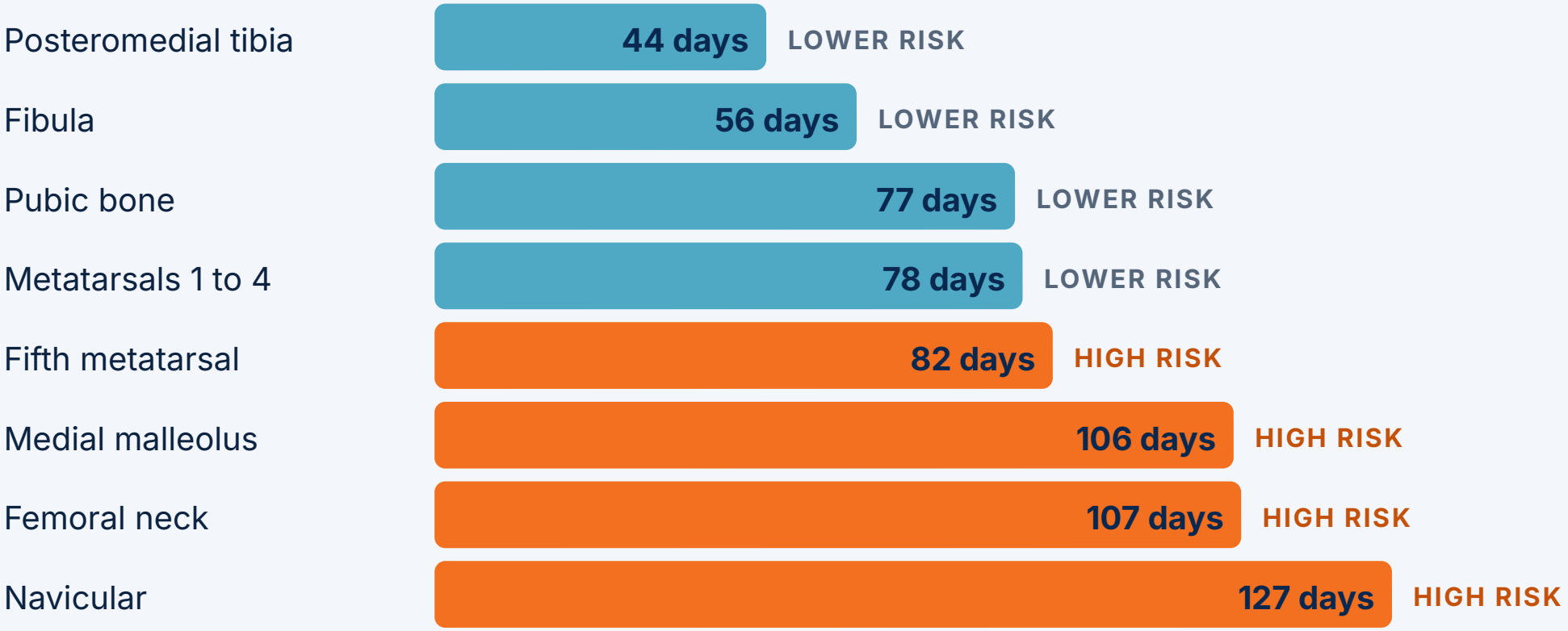

Source: Hoenig et al., Br J Sports Med 2023. Pooled means; individual athletes vary widely.

PART 3 · TIBIA DISCUSS

MTSS or tibial stress fracture?

Feature	MTSS	Tibial stress fracture
Pain pattern	Diffuse ache along the shin, often eases with warm-up.	Focal pain that builds with running. May ache at rest.
Tenderness	Diffuse, along the posteromedial border.	Focal, over one point on the bone.
Hop test	Usually tolerated.	Often reproduces the pain.
MRI	Periosteal oedema, marrow normal.	Marrow oedema, may show a cortical line.

Many see these as one continuum, not two diseases. Where do you draw the line in clinic?

Typical features only: there is overlap, and the MRI has to match the examination.

TIBIA · LOWER RISK

Posteromedial tibia



Example images shown in the live session



Example images shown in the live session

WHO

Runners, often the distal two thirds of the tibia.

COURSE

Lower-risk site. Pooled return to sport about 44 days.

WATCH FOR

Pain on the anterior cortex. That is a different problem.

TIBIA · HIGH RISK

The anterior cortex: the dreaded black line



Example images shown in the live session

WHY IT IS RISKY

The anterior tibia sits on the tension side. Complication rate was about 41% in pooled data.

BEST TEST

CT shows the cortical line best. MRI shows the oedema around it.

CLINICALLY

Focal anterior shin pain that persists with rest. Keep a low threshold to image and refer.

LOWER LEG · LOWER RISK

Fibula



Example images shown in the live session



Example images shown in the live session

COURSE

Pooled return to sport about 56 days.

CLINICALLY

Focal fibular tenderness and pain on hopping after a load increase.

PART 3 · FEMORAL NECK

Two sides of the neck, two different stories



Superior neck: tension side

Higher risk of the fracture completing and displacing. Needs an orthopaedic opinion about fixation.

Inferior neck: compression side

Usually managed with protected weight-bearing and a staged return. Still serious: do not run through it.

In pooled data

About 43% complication rate and about 107 days to return to sport.

PART 3 · FEMORAL NECK

The femoral neck plan

Compression side

- 2 weeks non-weight-bearing
- Then add 25% a week
- Walk-to-run progression, up to 4 months

Tension side

- Orthopaedic referral for fixation
- No running, protect weight-bearing
- Rehabilitation follows surgery

Work-up for both

- Vitamin D, calcium, PTH
- Consider bone density
- Screen energy availability

Summary of published management. Follow your local protocol and the orthopaedic team.

FOOT · LOWER RISK

Metatarsals 1 to 4



Example images shown in the live session



Example images shown in the live session

WHERE

The second and third metatarsals are common.

COURSE

Pooled return to sport about 78 days.

FOOT · HIGH RISK

Navicular



Example images shown in the live session



Example images shown in the live session

CLUE

Vague dorsal midfoot ache, tender over the navicular.

COURSE

Pooled return to sport about 127 days, the longest of any site here.

IMAGING

X-ray is often normal. MRI and CT find it.

FOOT AND ANKLE · HIGH RISK

Fifth metatarsal, sesamoids, malleolus



Fifth metatarsal

The proximal shaft heals slowly. Pooled return about 82 days.



Great toe sesamoid

Pain under the first MTP joint, worse on push-off.



Medial malleolus

Medial ankle pain on running or jumping. Pooled return about 106 days.

KNEE · INSUFFICIENCY FRACTURE

Subchondral insufficiency fracture



Example images shown in the live session

WHO

Typically over 55, more often women, usually one knee.

ON MRI

Subchondral low-signal line with marrow oedema, usually the medial femoral condyle.

OLD NAME

Spontaneous osteonecrosis (SONK), now often seen as an insufficiency fracture.

LINK

Meniscal tears, including root tears, are a recognised association.

PART 4

Cases and quiz

Pairs for the cases, then a six-question quiz. Your images, my questions.

CASE 1 OF 3 PAIRS

A teenage runner with six weeks of shin pain

- 17-year-old middle-distance runner, mileage doubled over winter
- Medial shin pain, now aching after every session
- Irregular menstrual cycles
- Focal tenderness on the tibia. Hopping reproduces the pain
- X-ray normal

YOUR QUESTIONS

Which grade? What else do you need to know? What is your plan?



Example images shown in the live session

CASE 1 · DISCUSSION

Grade the bone, then ask why

Imaging

Run the three-question ladder. Match the grade to the rest estimate, and note the site is lower risk.

Cause

A load jump, plus possible low energy availability (RED-S). Ask about intake, cycles and bone health.

Plan

Offload and cross-train, then a graded reload. Return when hop and palpation are pain-free.

> Involve the right people early: the doctor and a dietitian if RED-S is suspected, and the coach for the training plan.

CASE 2 OF 3 PAIRS

A marathon trainee with five weeks of groin pain

- 34-year-old, weekly mileage rising for a marathon
- Deep groin pain after runs, now when walking
- Pain at end-range hip rotation and on hopping
- Low vitamin D on recent bloods
- X-ray normal

YOUR QUESTIONS

Which side of the neck? Weight-bearing or not today? Who do you call?



Example images shown in the live session

CASE 2 · DISCUSSION

Which side of the neck decides the plan

Tension or compression?

Read the coronal image. Superior means tension: orthopaedic opinion on fixation. Inferior means compression.

Today

Stop running. Protect weight-bearing, with crutches, until the MRI is read.

Compression-side plan

2 weeks non-weight-bearing, then add 25% a week. Walk-to-run, up to 4 months.

> Work up the cause: vitamin D, calcium, PTH, bone density and energy availability.

CASE 3 OF 3 PAIRS

Sudden medial knee pain at 63

- Stepped off a kerb two weeks ago, no major injury
- Sharp medial knee pain, worse at night
- Walking is painful. Mild effusion
- X-ray normal or subtle flattening of the medial condyle

YOUR QUESTIONS

What is your differential? What do you tell her? What changes if the X-ray shows flattening?



Example images shown in the live session

CASE 3 · DISCUSSION

A knee that looked normal on X-ray

Likely

Subchondral insufficiency fracture of the medial femoral condyle, formerly called SONK.

MRI clues

A subchondral low-signal line with extensive marrow oedema. Check the menisci, including the roots.

Plan

Protected loading, pain control and early orthopaedic input. Repeat imaging if pain worsens.

> Outlook ranges from full recovery to collapse of the joint surface, so watch for a change in pain.

QUIZ · QUESTION 1 OF 6 PAIRS

Which finding defines Fredericson grade 4b?

A Periosteal oedema only

B Marrow oedema on STIR only

C Several foci of signal inside the cortex

D A linear fracture line

QUIZ · QUESTION 2 OF 6 PAIRS

Which femoral neck stress fracture usually needs an orthopaedic opinion on fixation?

A Compression side (inferior)

B Tension side (superior)

C Both sides are the same

D Neither: rest is always enough

QUIZ · QUESTION 3 OF 6 PAIRS

Which test shows the anterior tibial cortical line best?

A Plain X-ray

B Bone scan

C CT

D Ultrasound

QUIZ · QUESTION 4 OF 6 PAIRS

In pooled data, which site took longest to return to sport?

A Posteromedial tibia

B Fibula

C Pubic bone

D Navicular

QUIZ · QUESTION 5 OF 6 PAIRS

About what share of asymptomatic runners show MRI stress reactions?

A About 5%

B About 15%

C About 40%

D About 80%

QUIZ · QUESTION 6 OF 6 PAIRS

A 63-year-old has sudden medial knee pain. MRI shows a subchondral low-signal line and marrow oedema in the medial femoral condyle. Most likely?

A Medial collateral ligament sprain

B Subchondral insufficiency fracture

C Septic arthritis

D Patellar tendinopathy

QUIZ · ANSWERS

Quiz answers

Q	Answer	Why
1	D · A linear fracture line	The hallmark of grade 4b.
2	B · Tension side	Higher risk of displacement: discuss fixation.
3	C · CT	Best for the cortical line at the anterior tibia.
4	D · Navicular	About 127 days pooled, the longest.
5	C · About 40%	43% in one small series: correlate clinically.
6	B · Subchondral insufficiency fracture	Formerly SONK. Check the menisci.

WRAP-UP

Return to sport in four phases

1

Offload

Settle pain with walking. Cross-train without impact.

2

Reload

Add impact in steps: walking, then hopping.

3

Return to run

Walk-run intervals on soft, flat ground. Volume before speed.

4

Return to sport

Full training, then competition. Fix the driver.

> Progress when: no focal tenderness, pain-free hop, and no flare-up the next day.

An illustrative framework. Adapt to the site's risk and your local protocol.

WRAP-UP

Escalate early when...

- Groin or hip pain comes with a painful hop or end-range rotation
- There is focal tenderness at a high-risk site
- Pain at rest or at night is not settling
- There is no improvement after a fair period of offloading
- The MRI shows a tension-side femoral neck line
- There are signs of low energy availability or a fragility fracture

Who to call: sports physician or orthopaedics for the bone, a dietitian and doctor for RED-S.

TAKE-HOME

Five things to remember

1. A normal X-ray does not rule out a stress fracture.
2. Fredericson: periosteum, marrow, T1, cortex, then the line.
3. Know the high-risk sites before you load them.
4. The grade guides timing. The site and the athlete guide the plan.
5. Find the driver: load, energy availability, bone health.

LONDON SPORTS AND RHEUMATOLOGY IMAGING

Normal X-ray, still worried? Get the MRI.

MRI, 1.5T and 3T

Every scan reported by a consultant radiologist.

Ultrasound and injections

Scan, report and guided injection in one visit.

Quick

Same-day appointments. Reports usually within 24 hours.

For your own cases

Second opinions on outside scans, and CPD sessions for your team.

A stress injury with a normal X-ray is exactly what MRI is for: early sensitivity is about 88%, against about 10% for plain films.

TWO CLINICS

LSRI Harley Street

The Harley Street Hospital, 19 Harley Street, London W1G 9QJ

LSRI Northwest London, Harrow

Medic Care Direct, 62 Station Road, Harrow HA2 7SJ

www.LSRI.uk

0203 633 5040 · info@lsri.uk

Self-pay and major insurers welcome. Sensitivity figures: radiographs about 10% early, MRI about 88% (see References).

THANK YOU

Questions, and your own cases

Dr Prashant Sankaye

Consultant Musculoskeletal, Sports and Spine Radiologist



LSRI

LONDON SPORTS IMAGING

BOOK OR REFER

www.LSRI.uk

0203 633 5040

info@lsri.uk

REFERENCES

Where the numbers come from

- Fredericson M, et al. Tibial stress reaction in runners: an MRI grading system. Am J Sports Med 1995.
- Arendt E, et al. Stress injuries to bone in college athletes. Am J Sports Med 2003.
- Kijowski R, et al. Validation of an MRI classification system for tibial stress injuries. AJR 2012.
- Bergman AG, et al. Asymptomatic tibial stress reactions: MRI in distance runners. AJR 2004.
- Boden BP, Osbahr DC. High-risk stress fractures: evaluation and treatment. J Am Acad Orthop Surg 2000.
- Hoenig T, et al. Return to sport after stress fractures, pooled analysis by site. Br J Sports Med 2023.
- Radiopaedia. Spontaneous osteonecrosis of the knee (radiopaedia.org).
- Sports Medicine Review: femoral neck stress fractures. Aspetar: imaging of tibial stress injuries.

LONDON SPORTS & RHEUMATOLOGY IMAGING

Teaching and MDT sessions for your team

Dr Sankaye runs dedicated teaching sessions and MSK imaging MDT meetings for physiotherapy, chiropractic, podiatry, osteopathy and sports therapy teams, and for GP practices. Bring your own cases and scans.

Call +44 20 3633 5040 · info@lsri.uk

More free slides: lsri.uk/cpd-accredited-training/teaching-slides/

LSRI Harley Street, W1G 9QJ · LSRI Northwest London, Harrow HA2 7SJ

LSRI Ltd is a CPD Approved Provider (#790052, The CPD Group). These slides are free educational material for healthcare professionals and are not a substitute for clinical judgement or local guidelines. Any patient images have been anonymised, and slides that could not be anonymised have been removed. You may share this PDF unchanged for non-commercial teaching.